

A Minimally Invasive Technique to Repair Pectus Carinatum. Preliminary Report

H. Abramson

Hospital del Tórax Antonio A. Cetrangolo, Vicente López, Provincia de Buenos Aires, República Argentina.

The present report deals with a new technique for the correction of pectus carinatum. Although less frequent than pectus excavatum, this deformity leads to numerous consultations, as it is difficult to conceal and affects the personality and behavior of many young patients.

We report the case of a 13-year-old boy with asymmetrical pectus carinatum. The chest wall was compressible, so the protrusion was corrected by means of intrathoracic compression. In this technique, the sternochondral region is compressed by implanting a metal bar in the presternal region and securing it bilaterally to the posterolateral portion of the costal arches. The strut remains implanted until remodeling of the chest contour is achieved. In this case, the strut was removed after 1 year and the new chest contour has been maintained unchanged more than 8 months following surgery.

In conclusion, this minimally invasive technique for the treatment of pectus carinatum by means of intrathoracic compression appears to be a valid alternative to more invasive techniques and should be considered in appropriate cases.

Key words: Pectus carinatum. *Minimally invasive surgery. Minimal access. Thorax abnormalities.*

Método miniinvasivo para la corrección del *pectus carinatum*. Comunicación preliminar

El presente trabajo trata sobre un nuevo sistema de corrección del *pectus carinatum*. Aunque menos frecuente que el *pectus excavatum*, esta anomalía es causa de numerosas consultas, pues es difícil de disimular y produce afectación de la personalidad y de la conducta en numerosos pacientes jóvenes.

Se presenta el caso de un paciente de 13 años con *pectus carinatum* asimétrico. La pared torácica era compresible. Se utilizó el denominado sistema de compresión endotorácica, por el cual se corrige la prominencia mediante la compresión de la región esternocondral implantando una placa metálica preesternal fijada bilateralmente a los arcos costales en su porción posterolateral, la cual permanece implantada hasta lograr la osificación de acuerdo con el contorno torácico obtenido y posteriormente se extrae. Se logró un resultado satisfactorio. El dolor postoperatorio fue aceptable. El implante se retiró al año y el nuevo contorno torácico se mantenía sin alteraciones a más de 8 meses de seguimiento.

En conclusión, el método miniinvasivo para el tratamiento del *pectus carinatum* mediante el sistema de compresión endotorácica parece una alternativa válida a los métodos más invasivos y debe tenerse en cuenta para aplicarlo en los casos adecuados.

Palabras clave: Pectus carinatum. *Cirugía miniinvasiva. Accesos mínimos. Anomalías torácicas.*

Introduction

Pectus carinatum is a chest wall deformity that mainly affects males and is less common than pectus excavatum. As the malformation is difficult to conceal, patients often ask to have it corrected. During the growth spurt of puberty the condition becomes more obvious and frequently produces changes in the behavior and personality of those who suffer from it.

Correspondence: Dr. H. Abramson.
Hospital del Tórax Antonio A. Cetrangolo.
Italia, 1750. Vicente López. Buenos Aires. 1638 República Argentina.
E-mail: habramson@intramed.net.ar

Manuscript received June 10, 2004. Accepted for publication September 22, 2004.

The so-called chondrogladiolar form of the condition is the most common variant: the sternal body protrudes and there is usually a lateral depression of the costal cartilages. The chest wall may also exhibit an asymmetrical shape characterized by the growth and prominence of one side of the chest with contralateral depression and rotation of the sternum. The procedure described in the present study is an original technique and comes under the category of minimally invasive surgery. In this technique, correction of the chest contour and simultaneous lateral expansion of the depressed costochondral arches are achieved by compressing the protruding anterior region of the chest wall.

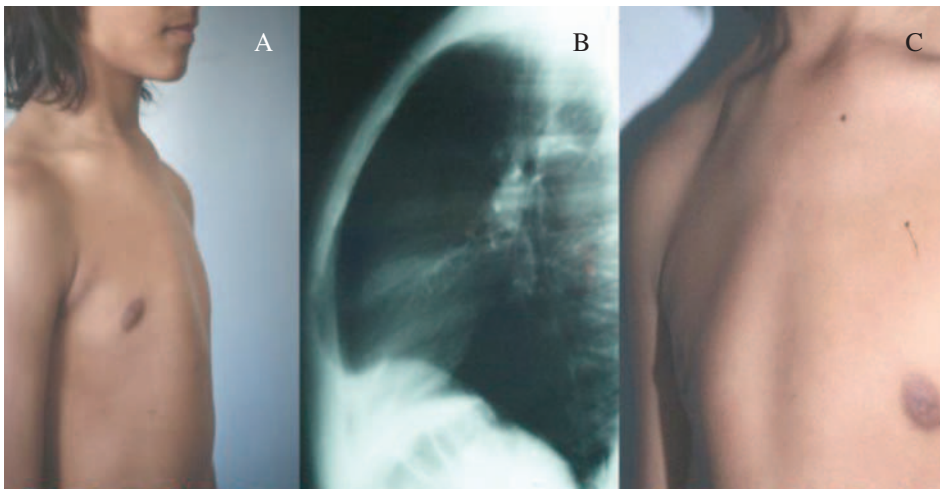


Figure 1. Thirteen-year old boy. Preoperative images: right oblique view (A), preoperative x-ray (B), and left oblique view (C).

Case Description

The patient was a 13-year old boy with asymmetrical pectus carinatum. The chest wall was compressible. To correct the protrusion we used intrathoracic compression, in which the sternochondral region is compressed by implanting a metal bar in the presternal region and securing it bilaterally to the posterolateral portion of the costal arches. The strut remains implanted until remodeling of the chest contour is achieved, at which point it is removed. Since January 1, 2002, the technique has been used on 10 patients. We describe the case of the first of these, for whom the entire process has been completed.

The patient, who had no significant medical or surgical history, presented with asymmetrical pectus carinatum that had appeared when he was approximately 7 years old and had increased in volume up to the time of surgery (Figures 1A and C). The boy weighed 55 kg and was 1.65 m tall. Cardiac function and lung function were normal. The patient showed a firm desire to have the malformation corrected because of its negative effects on his self-image and social life. A lateral chest x-ray showed the sternum curving forward (Figure 1B). Bilateral expansion of the costal arches and cartilages of the lower axillary region was observed, indicating that the anterior region of the chest was compressible.

Adequate elasticity of the chest is a key factor in effective molding of the chest wall. The ideal time for the operation is the period of rapid body growth. The compression system acts in a way similar to that of orthodontic braces. The intrathoracic compression system (US Patent Document Number, 20040117016) consists of a compression strut and stabilizing bars made of 316L steel. The 2 stabilizing bars, which are fixed to the compression strut with screws, are rectangular in shape with threaded holes along a groove in the central portion and 2 holes at the ends that allow the bars to be attached to the ribs by means of steel wire suture.

Benders were used to mold the compression strut into a convex shape in accordance with the particular characteristics of the malformation. There were no intraoperative or immediate postoperative complications. The patient was released 4 days after surgery. Postoperative pain was mild and the patient returned to school after 10 days. At 8 months and 11 months following surgery seromas developed along the compression strut and around the stabilizers and were drained through a needle. The implant was removed 1 year after surgery. The curved compression strut was extracted with no need for rotation. The degree of sternal correction and the final cosmetic result were very satisfactory, as can be seen in Figures 2A and B, and have been maintained during the 8-month follow-up period from removal of the strut to the present time (Figures 3A and B).

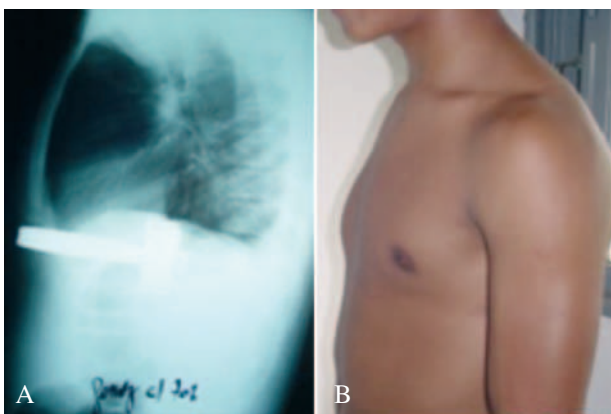


Figure 2. Result 1 year after surgery.

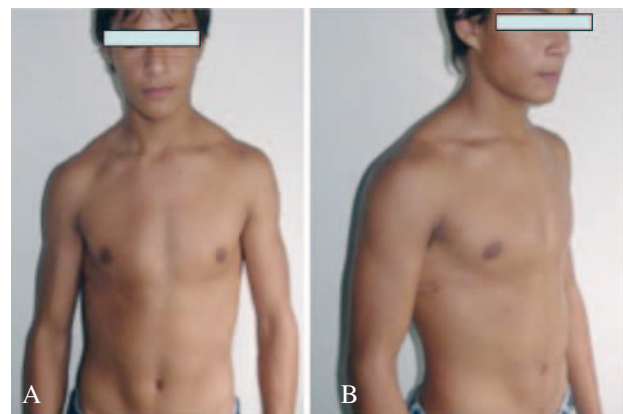


Figure 3. Result 6 months after withdrawal of implant.

Discussion

Classic techniques for the repair of chest deformities are highly invasive procedures. The history of corrective surgery for pectus carinatum is relatively recent. Ravitch^{1,2} reported his first experiences in 1952 and 1960. Roviscek et al³ in 1963 and Welsh and Vos⁴ in 1973 described their experiences with methods that have been used with no major modification up to the present time. All of these surgical procedures, while providing acceptable results, require large incisions, the creation of large skin and muscle flaps, the resection of costochondral arches, and sternal osteotomies. Such techniques are laborious and have the disadvantage of leaving sequelae such as keloid scars.

More recently some success has been reported with orthoses that exert pressure on the protruding portion of the chest wall.^{5,6} However, such methods are awkward, expensive, time consuming, and offer uncertain results.

It is appropriate, then, to debate the merits of traditional surgical repair treatments and a new minimally invasive technique. By means of the compression (rather than resection) method, correction can be achieved with no need for techniques involving extensive cutaneous incisions, large skin and muscle flaps, resection of variable portions of the costochondral arches, sternal osteotomy, and various forms of reconstruction including muscle reimplantation. The result, considered in terms of the contour of the chest wall and its anatomical characteristics, is comparable to that obtained by means of the various invasive techniques used in the principal hospitals that specialize in those approaches. The late development of chest wall rigidity that may occur when parietal resection is performed is also avoided.⁷ Like the minimally invasive treatment of pectus excavatum by the Nuss technique,^{8,9} the minimally invasive technique for the correction of pectus carinatum described in this study has none of the disadvantages associated with techniques based on the resection of chest wall structures.

Tolerance of the implant was good. However, in the light of our experience with the present case and some later ones, we recommend massaging the skin covering the implant in order to avoid seromas, skin hyperpigmentation,

and adherence of the implant to the superficial fascia. Special precautions should be taken to ensure that the compression strut does not exert excessive pressure on the anterior sternal table. In conclusion, the results of our initial experience with this new minimally invasive technique for the treatment of pectus carinatum were very favorable. The degree of correction obtained was satisfactory. Observation and follow-up of initial cases over a longer period of time are needed to evaluate the technique properly. The appropriate length of time that the implant should remain in place also needs to be determined, taking into account the growth process of each individual patient.

Acknowledgments

We would like to express our admiration and gratitude to Professor Donald Nuss, whose revolutionary procedure for the treatment of pectus excavatum inspired us to look for a minimally invasive way to treat pectus carinatum.

REFERENCES

1. Ravitch MM. Unusual sternal deformity with cardiac symptoms—operative correction. *J Thorac Surg.* 1952;23:138-44.
2. Ravitch MM. The operative correction of pectus carinatum (pigeon breast). *Ann Surg.* 1960;151:705-14.
3. Roviscek F, Sanger PW, Taylor FH. The surgical treatment of chondrosternal prominence (pectus carinatum). *J Thorac Cardiovasc Surg.* 1963;45:691-701.
4. Welsh KJ, Vos A. Surgical correction of pectus carinatum (pigeon breast). *J Pediatr Surg.* 1973;8:659-67.
5. Haje SA, Bowen JR. Preliminary results of orthotic treatment of pectus deformities in children and adolescents. *J Pediatr Orthop.* 1992;12:795-800.
6. Vidal J, Nakach G. Tratamiento ortopédico de las deformaciones torácicas. In: Villadot R, Cohí O, Clavell S, editors. *Ortesis y prótesis del aparato locomotor. Columna vertebral.* Barcelona: Masson; 1994. p. 85-93.
7. Shamberger RC, Welch KJ. Surgical repair of pectus excavatum. *J Pediatr Surg.* 1988;23:615-22.
8. Nuss D, Kelly RE, Croitoru DP, Katz ME. A 10-year review of a minimally invasive technique for the correction of pectus excavatum. *J Pediatr Surg.* 1988;33:545-52.
9. Croitoru DP, Kelly RE, Goretsky MJ, Lawson ML, Swoveland B, Nuss D. Experience and modification update for the minimally invasive Nuss technique for pectus excavatum repair in 303 patients. *J Pediatr Surg.* 2002;37:437-45.