

Absorbable Stabilisation of the Bar in Minimally Invasive Repair of Pectus Excavatum

Authors

M. Torre¹, V. Jasonni¹, C. Asquasciati¹, S. Costanzo¹, M. V. Romanini², P. Varela³

Affiliations

¹ Pediatric Surgery, G. Gaslini Institute, Genova, Italy

² Plastic Surgery, IST, University of Genova, Genova, Italy

³ Pediatric Surgery, Calvo Mackenna Hospital, Santiago, Chile

Key words

- pectus excavatum
- thoracic malformations
- minimally invasive repair of pectus excavatum

Abstract



Introduction: The minimally invasive repair of pectus excavatum has become the preferred technique in most centres. One of the most important technical points for the final result is stabilisation of the bar, usually obtained by one or two metal stabilisers. Recently, long-term absorbable stabilisers have become available (LactoSorb[®], Biomet, Jacksonville, FL, USA). Made of poly-L-lactic and polyglycolic acid, they have been introduced with the aim of reducing local discomfort and making removal of the bar easier. Their efficacy for the stabilisation of the bar has not been proved yet. In this paper we compare the surgical outcome in two groups of patients, one treated with metallic and the other with absorbable stabilisers.

Material and Methods: A total of 280 patients underwent pectus excavatum repair using a Nuss technique in two centres. In 194 patients (group 1), operated on since 2001, the metallic stabiliser was used. In 86 patients (group 2), operated on since February 2007, the LactoSorb[®] stabiliser was preferred. We compared both groups in terms of surgical details, local symptoms or complications, and bar instability rate.

Results: The surgical technique for the stabilisation of the bar was identical in both groups, but in group 1 the stabiliser was fastened to the bar with a steel wire, while in group 2 polyglycolic sutures were used. No differences in local discomfort or postoperative pain were observed between the groups. The LactoSorb[®] stabiliser was palpable for at least 6–9 months, and progressively disappeared at 9–12 months. In group 1 we observed 6 local complications. In particular, two patients presented with infection, one of them associated with a skin lesion and opening over the metallic stabiliser (revision of the wound was performed). Another patient developed a thoracic wall haematoma after suffering a trauma over the metallic stabiliser, 13 months after operation. Three patients developed a seroma. In group 2 we observed 3 subcutaneous swellings at the site of the LactoSorb[®] stabiliser at 6, 8 and 9 months after the operation. We did not observe either skin lesions or infections. In the group with metallic stabiliser, 3 patients (1.5%) had bar dislocation, while we did not observe bar instability in the group with LactoSorb[®] stabiliser.

Conclusions: LactoSorb[®] stabiliser is safe and effective for stabilising the bar in pectus surgery. We suggest its routine use as it appears to be less traumatic and could make bar removal easier.

received September 9, 2008
accepted after revision
November 5, 2008

Bibliography

DOI 10.1055/s-2008-1039176
Published ahead of print:
5 December 2008
Eur J Pediatr Surg 2008; 18:
407–409 © Georg Thieme
Verlag KG Stuttgart · New York ·
ISSN 0939-7248

Correspondence

M. Torre
Pediatric Surgery
G. Gaslini Institute
Largo G. Gaslini 5
16148 Genova
Italy
micheletorre@hotmail.com

Introduction



Bar displacement is one of the most serious complications of minimally invasive repair of pectus excavatum (MIRPE) [7,8]. Many techniques have been proposed to increase the stability of the bar [2,3,10]. Most surgeons fix the bar with the help of one or two metallic stabilisers [4,6]. At the time of bar removal, the metallic stabiliser has to be dissected and detached from the bar; in cases with a bilateral stabiliser two incisions have to be performed.

Recently, absorbable stabilisers have become available (LactoSorb[®] stabiliser, Biomet, Jacksonville, FL, USA). They are made of poly-L-lactic and polyglycolic acid, and are completely absorbed by 12 months. This material has been used for many years in other kinds of surgery (craniofacial, orthopaedic surgery), and has been proven to be safe in children [1]. The absorbable stabiliser was introduced in pectus surgery with the aim of reducing local complications and discomfort, and making bar removal easier. In cases requiring bilateral stabilisation the double incision is avoided.

The efficacy of the LactoSorb® stabiliser for the stabilisation of the bar has not been proved yet. The aim of our paper was to compare two groups of patients, one treated with metallic and the other with absorbable stabilisers.

Materials and Methods

This is a retrospective study on patient series from two centres which have used MIRPE and the Nuss technique [6] since 2001 and 2005, respectively. The technical details for stabilisation are the same for both centres: one stabiliser on the left, 4 stitches between the bar and the adjacent ribs on the right.

The LactoSorb® stabiliser has been used in both centres since 2007. Once introduced, in one centre it was used in all patients; in the other centre, the LactoSorb® stabiliser has been used in all patients under 15 years of age, while the metallic stabiliser was still preferred for patients over 15 years of age (considered at greater risk of destabilisation). The LactoSorb® stabiliser has the same shape and size as the metallic one, it has the same holes (see **Fig. 1**) and is transparent.

All patients operated with MIRPE in both centres were considered. Patients were divided into two groups. Group 1 (metallic stabilisation) included all patients in whom stabilisation was achieved with a left-sided metallic stabiliser (172 cases) and a minority of patients (22 cases) at the beginning of our experience who underwent stabilisation on both sides. The total number of patients included in group 1 was 194.

Group 2 (LactoSorb® stabilisation) included all patients operated on since February 2007 in one centre and since March 2007 in the other, in whom stabilisation was achieved by an absorbable LactoSorb® stabiliser on the left side. None of the patients in this group received bilateral stabilisers. The total number of patients included in group 2 was 86. Two bars (and two stabilisers) were inserted only in very selected cases (4 patients in each group), when one bar alone was unable to correct the thoracic defect.

The following were evaluated for both groups: technical details, discomfort associated with the presence of the stabiliser, local complications, instability rate. In all patients of group 2 the bar is still in site, so we could not compare bar removal between the two groups.

Student *t*-test was used for statistical analysis to compare the parameters of the two groups (age of the patients, pain score, and hospitalisation length).

Results

MIRPE according to Nuss [5] was performed in a total of 280 patients in the two centres. In group 1 (194 patients with metallic stabilisation) the follow-up ranged from 6 to 87 months, with a mean follow-up of 45 months.

In group 2 (86 patients with LactoSorb® stabilisation) the mean follow-up was 12 months, with a standard deviation (SD) of 4.7, and a range from 5 to 20 months. The mean age of group 2 patients was 15.5 (3.4 SD), and ranged between 6 and 22 years. No statistical differences were found between the groups regarding age at surgery.

The technical details of the stabilisation were similar for both groups. The metallic stabiliser was fastened to the bar with a steel wire, while the LactoSorb® stabiliser was secured with a polyglycolic suture. In both groups other absorbable stitches

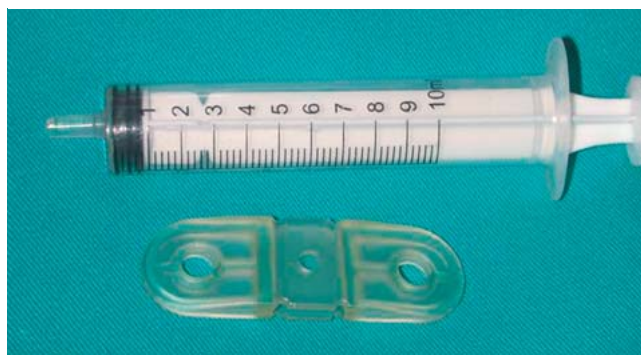


Fig. 1 LactoSorb® stabiliser.

were passed through the holes of the stabiliser fixing it to the pectoral muscles. This manoeuvre was easier in patients in group 2, because the surgeon was able to see the needle through the transparent stabiliser.

No differences were observed between the groups with regard to postoperative pain or hospitalisation. In both groups, pain was managed during the first three days by a peridural infusion of fentanyl and levobupivacaine, associated with intravenous boluses of paracetamol and/or ketorolac. After the fourth day, only oral paracetamol and codeine were given. Pain was evaluated with a pain numeric score from 1 to 10, and analgesia doses were adjusted accordingly. None of the patients in both groups reported significant (requiring medication) local discomfort.

The LactoSorb® stabiliser was palpable under the skin for 6–9 months. After approximately 3 months it started to change its shape and became slightly mobile. At 6–9 months the stabiliser was progressively less palpable and between 9 and 12 months it was no longer completely palpable.

Local complications were reported in 6 cases of group 1 (3%). Wound infection was observed in 2 cases. In one of them (a very slim 13-year-old boy) the skin over the metallic stabiliser started to damage and opened at 2 months after the operation. Three weeks after wound revision, the skin opened again; a Goretex sheet was then placed over the metallic stabiliser and the skin was closed; no other troubles were observed. Another patient developed a haematoma of the thoracic wall at the site of the stabiliser after a local trauma, at 13 months from the operation. Three patients developed a seroma (two of them with bilateral metallic stabilisers).

In group 2 we did not observe any infections. Three patients (3.5%) developed a subcutaneous collection at the site of the stabiliser at 6, 8 and 9 months from the operation, respectively. We tried to puncture it: in two of them we obtained few ml of fluid (culture examination was negative), in the third case no free liquid was collected. In all of these cases the absorption was complete after several days.

The bar was instable in 3 cases (1.5%) of group 1, while none of group 2 had this complication.

Discussion

The lateral stabiliser has been demonstrated to be a very effective tool which contributes to the stability of the bar after pectus repair [4,5]. However, metallic stabilisers can become a source of trouble, and some authors prefer not to use them. An in-

creased incidence of wound complications (dermatitis, seroma, infections) associated with the use of local stabilisers has been reported [11].

The introduction of a new absorbable stabiliser (LactoSorb®) had the aim of reducing these complications and making bar removal easier. This material has previously been used for a long time in humans without adverse effects; however one possible concern could regard the efficacy of a device which loses its strength and disappears within a few months. Although our results are preliminary and a longer follow-up is required, the most important finding of the present study is the efficacy of LactoSorb® stabiliser in fixing the bar. According to our data, it appears even superior to metallic stabilisers, but in our opinion this difference was not significant, because the patients' numbers and surgeons' experience were different between the two groups. The efficacy of LactoSorb® in stabilising the bar over a longer period, despite its progressive absorption after few months, could be explained by the formation of adhesions and calcifications around the bar. Local complications were rare in both groups. One specific complication of the absorbable stabiliser was the subcutaneous collection we observed in three cases during the process of absorption of the LactoSorb®. Actually this was clinically not particularly relevant and culture examinations excluded infection. We think that this fluid or semi-fluid collection may be due to the dissolution and substitution of the LactoSorb® material during the absorption process, and therefore we consider it more as part of this process than as a true complication. In contrast, the metallic stabiliser probably contributed to the local complications observed in group 1, in particular infections, opening of the skin and post-traumatic haematoma.

Another specific advantage of the absorbable stabiliser was an easier and faster dissection of the tip of the bar at the time of its removal. Actually, the dissection of the metallic stabiliser, often covered by scar tissue or bone, and detachment of the stabiliser from the bar, can be sometimes quite difficult and time consuming procedures, so that a new instrument has been introduced to make these manoeuvres easier [9]. It is logical to expect an easier and less traumatic removal of the absorbable stabiliser, but this remains to be investigated.

In conclusion, this is the first report in which the results of absorbable stabilisation are shown. The LactoSorb® stabiliser is safe and as effective as the metallic stabiliser in fixing the bar. We suggest the routine use of the LactoSorb® stabiliser, as it appears to be less traumatic and requires less dissection at the time of bar removal.

Conflict of Interest: None

References

- 1 Barry L, Eppley. Use of resorbable plates in pediatric facial fractures. *J Oral Maxillofac Surg* 2005; 63: 385–391
- 2 Hebra A, Swoveland B, Egbert M, Tagge EP, Georgeson K, Othersen Jr HB, Nuss D. Outcome analysis of minimally invasive repair of pectus excavatum: review of 251 cases. *J Pediatr Surg* 2000; 35: 252–257; discussion 257–258
- 3 Hebra A, Gauderer MW, Tagge EP, Adamson WT, Othersen Jr HB. A simple technique for preventing bar displacement with the Nuss repair of pectus excavatum. *J Pediatr Surg* 2001; 36: 1266–1268
- 4 Hosie S, Sitkiewicz T, Petersen C, Göbel P, Schaarschmidt K, Till H, Noatnick M, Winiker H, Hagl C, Schmedding A, Waag KL. Minimally invasive repair of pectus excavatum – the Nuss procedure. A European multi-centre experience. *Eur J Pediatr Surg* 2002; 12: 235–238
- 5 Nuss D, Croitoru DP, Kelly Jr RE, Goretsky MJ, Nuss KJ, Gustin TS. Review and discussion of the complications of minimally invasive pectus excavatum repair. *Eur J Pediatr Surg* 2002; 12: 230–234
- 6 Nuss D, Kelly RE, Croitoru DP, Katz ME. A 10 year review of a minimally invasive technique for the correction of pectus excavatum. *J Pediatr Surg* 1998; 33: 545–552
- 7 Park HJ, Chung WJ, Lee IS, Kim KT. Mechanism of bar displacement and corresponding bar fixation techniques in minimally invasive repair of pectus excavatum. *J Pediatr Surg* 2008; 43: 74–78
- 8 Petersen C, Leonhardt J, Duderstadt M, Karck M, Ure BM. Minimally invasive repair of pectus excavatum – shifting the paradigm? *Eur J Pediatr Surg* 2006; 16: 75–78
- 9 Saxena AK. Pectus bar removal after minimal invasive repair of pectus excavatum: advantages of bar stabilizer anvil tool. *Ann Thorac Surg* 2007; 84: 1364–1366
- 10 Uemura S, Nakagawa Y, Yoshida A, Choda Y. Experience in 100 cases with the Nuss procedure using a technique for stabilization of the pectus bar. *Pediatr Surg Int* 2003; 19: 186–189
- 11 Watanabe A, Watanabe T, Obama T, Oshawa H, Mawatari T, Ichimiya Y, Abe T. The use of a lateral stabilizer increases the incidence of wound trouble following the Nuss procedure. *Ann Thorac Surg* 2004; 77: 296–300